

## Tip Rhinoplasty in Cleft Lip Nasal Deformity

SAMEH ELNOAMANI, M.D.\*; MOHAMED HAZEM, M.D.\* and AYMAN M. ABDELMOFEED, M.D.\*\*

*The Department of Plastic Surgery, Faculty of Medicine, Cairo\* and Benha\*\* Universities*

### ABSTRACT

**Introduction:** The cleft nasal deformity is a complex challenge in plastic surgery involving the skin, cartilage, mucosa, and skeletal platform. The appropriate approach has been extensively debated in the literature with respect to timing, technique, and extent of surgical intervention.

**Aim:** The aim of current work is to study the different surgical options for reconstruction of the nasal tip in cases of secondary cleft lip nasal deformity, to evaluate their esthetic and functional results and demonstrating the subjective satisfaction for each case.

**Patients and Methods:** Twenty five patients having cleft lip nasal deformity underwent rhinoplasty to correct the nasal deformity in which the definition and position of the nasal tip were the corner stones in evaluating the net aesthetic result. All study patients underwent tip rhinoplasty in the form of suturing as well as grafting. They underwent some secondary procedures like, pyriform aperture augmentation, dorsum correction, alar rim and web correction, air way patency, and corrective osteotomies.

**Results:** Subjective evaluation results of current study were generally promising; 44% of patients were happy of their nasal job, 48% showed fair response, while 8% were unhappy. Most of happy patients were males, they obtained their cartilage grafts from the costal cartilage. The objective judgement of the rhinoplasties done in the study showed that 80% of patients had accepted net nasal tip while 20% had residual deformity in the form of wide, bulky, or deviated tip. The residual tip deformity came mainly after use of auricular graft, after using tip suturing and diced cartilage on top. Post-operative secondary deformities were few in the form of asymmetrical nose, obtuse naso-facial angle, alar web, or unpleasant lip scar. All patients that had an obstructed airway before the operation had improved, while 30% of those who had nasal tone showed improvement after the operation.

**Conclusion:** Nasal grafts are essential for considerable good outcomes for cases of cleft nasal deformity. Autologous cartilaginous grafts are the most suitable type of nasal grafts, and costal cartilage graft is the most superior between them. Further studies are needed to justice if primary rhinoplasty is beneficial or it disturbs the nasal symmetry and leave scared tissues for a potential future intervention.

**Key Words:** Tip – Rhinoplasty – Cleft – Lip.

### INTRODUCTION

The cleft nasal deformity is a complex challenge in plastic surgery involving the skin, cartilage, mucosa, and skeletal platform. Ever since Blair and Brown first described the intricacies of the cleft pathology in 1931 [1], the appropriate approach has been extensively debated in the literature with respect to timing, technique, and extent of surgical intervention.

It is important to identify the aim of the rhinoplasty in cleft lip nasal deformities as to restore the nasal symmetry, improvement of the nasolabial and naso-facial relationship with minimal evidence of surgical intervention as well as the functional objectives as patent air way, proper position of the maxilla and achievement of normal speech [2]. Rhinoplasty in cleft lip nasal deformities could be performed either primary or secondary after repair of the cleft lip. Primary correction has been reappraised in the last two decades having particular advantages as more symmetrical nose and better appearance in the early life. Even when rhinoplasty is re-required after nasal growth is complete, the deformity is less severe and more amenable final results [3].

The secondary surgery to further modify the nasal shape is often necessary in the teen years. The secondary deformities include depressed nasal tip with diastatic lower lateral cartilage, wide alae, large nostrils short columella, wide prolabium with lack of philtral and Cupid's bow definition, shallow buccal sulcus, tight upper lip, irregular scars and central vermilion insufficiency [4].

The aim of current thesis is to study the different surgical options for reconstruction of the nasal tip in cases of secondary cleft lip nasal deformity, evaluate of their esthetic and functional results and demonstrate the subjective satisfaction for each case.

## PATIENTS AND METHODS

In current study, twenty five patients having cleft lip nasal deformity underwent rhinoplasty to correct the nasal deformity in which the definition and position of the nasal tip were the corner stones in evaluation of the net aesthetic result. These patients were managed in Kasr El Aini and Benha University hospitals during the period from January 2012 to June 2014.

All the patients who participated in this study had late cleft lip nasal deformities, either with no previous attempts was performed for cleft lip repair (4 patients) or repaired cleft lip (21 patients). The secondary nasal deformity resulted from either insufficient primary rhinoplasty during early repair of the cleft lip with residual secondary nasal deformity (5 patients) or not previously repaired cleft lip nasal deformity (20 patients). Out of the 25 patients, only 3 patients had bilateral cleft lip, while the other 22 patients had unilateral cleft lip.

The age of the patients ranged from thirteen years to thirty one years (average 17 years). There were fourteen females and eleven males.

### *Preoperative assessment:*

All patients underwent complete history taking and clinical examination. The nasal deformities were recorded in details together with any residual deformity in the lip.

Out of the 25 patients, four patients had no previous attempts for repair of the cleft lip. Twelve cases had unpleasant scar from the previous operation. Five cases had short lip. Seven cases had notched vermillion. Ten of the patients had irregularities in the white line. Septal deviation was detected in nine patients. The nasal dorsum was deficient (saddle) in 16 patient, humpy (over projecting) in 6 cases and apparently normal in the rest 3 patients (Fig. 1).

### *Operative technique:*

All surgeries in current study were done under general anesthesia. A conformed oral endotracheal tube fixed on the chin in the midline. A throat pack was carefully placed in the posterior oropharynx. A low mean arterial pressure was maintained during surgery to maintain a dry surgical field.

### *Lip revision:*

In the four cases of the unrepaired cleft lip, Millard repair were performed in the same set before the nasal repair. In the twelve cases having unsatisfactory scarring of previous cleft lip repair, excision of the old scar was performed, including

skin, subcutaneous tissue, and minimal part of the underlying muscles. Closure was done in three layers. The five cases complaining of short lip following previous repair of cleft lip, Z plasty was done for elongation of the philtrum for one of them. Among the seven cases with notched vermillion following previous cleft lip surgery, four cases with minimal notching were treated by horizontal incision in the vermillion at the center of the notch. Then this incision was closed vertically. The other three cases were treated by advancement flap similar to Millard advancement flap. In the ten patients having irregularities in the white line, seven of them were treated by diamond shape excision of the protruding vermillion then careful approximation of the vermillion cutaneous junction preserving the continuity of the white line. The remaining three patients were treated by Z-plasty to reorient the tissues. Thus restoring the continuity of the white line.

### *Management of the nasal deformity:*

Open rhinoplasty approach was applied to all cases.

### *Primary procedures for tip rhinoplasty:*

The cartilaginous framework was freed from the mucosa and the skin. The lower lateral cartilage was found to be deformed in all patients. In all patients the lower lateral cartilage was freed and the lateral crus was exposed (Fig. 2).

Septoplasty is usually performed first to correct functional problems and obtain any cartilage that may be necessary for grafting. The anterior septal angle is easily identified, and soft tissue is removed from between the medial crura down to the pre-maxilla. This provides excellent exposure of the caudal septum and allows the columella to be narrowed.

The upper lateral cartilages are separated from the septum such that the nasal dorsum and septum are "ouvert au ciel" (open to the sky).

*Then, the nasal tip is managed according to the intra-operative findings:*

- All patients needed tip rhinoplasty by using both tip sutures as well as tip grafts.
- Tip grafts are indicated in all patients due to:
  - 1- A short infratip lobule segment that cannot be corrected by borrowing from the medial crus.
  - 2- To increase and maintain tip projection.
  - 3- To shape the nasal domes and the columella.
  - 4- To add support to the dorsum.

- 5- To add support to the lateral crura.
- 6- Inability to achieve the desired look in the tip using non-destructive techniques and the normal anatomy.
- 7- To create visible angularity beneath extremely thick tip skin.

- Three types of tip grafts were used costal cartilage graft (14 patients), septal cartilage graft (7 patients) and auricular cartilage graft (4 patients). (Fig. 3)
- The types of used tip sutures and tip grafts are demonstrated in (Tables 1,2).

Fig. (1): Various lip deformities:

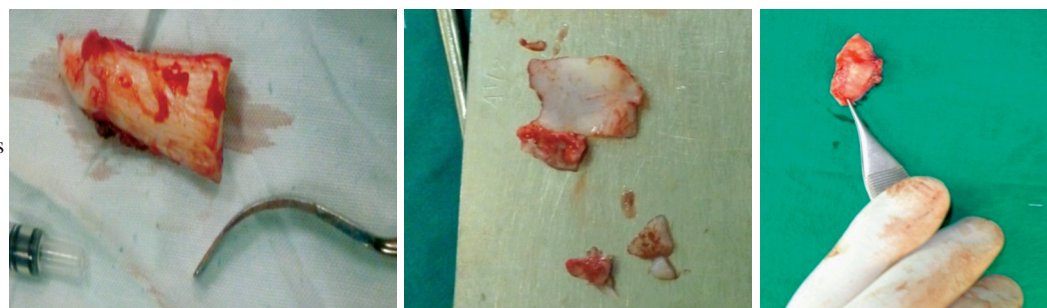
- (A): Male patient with unpleasant lip scar
- (B): Female patient with irregular white line
- (C): Male patient with unpaired cleft lip
- (D): Female patient with notched vermilion.

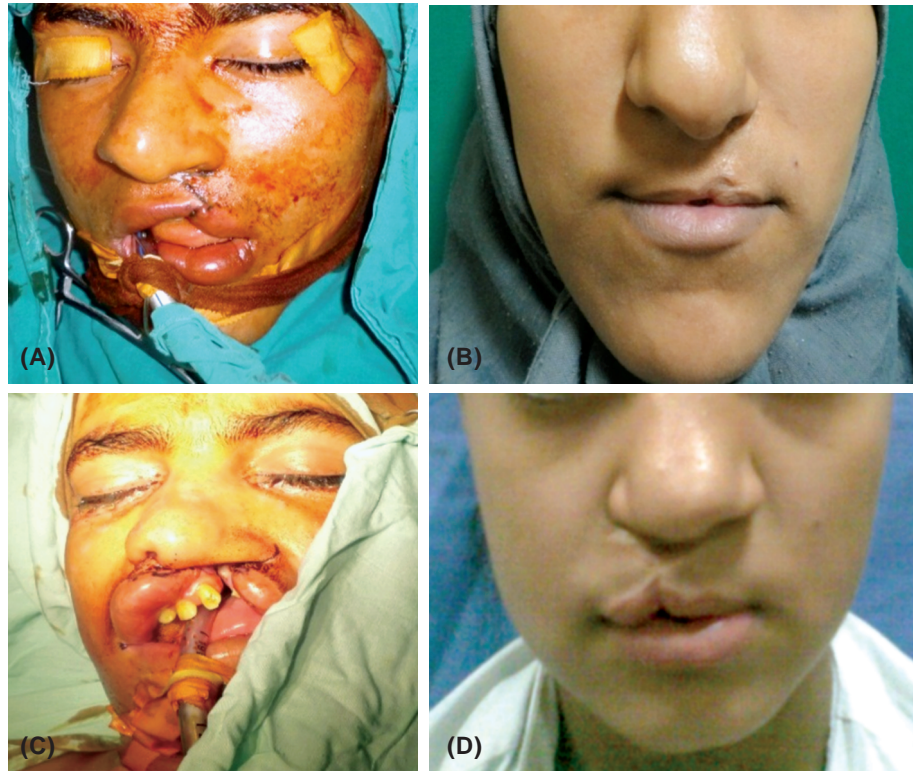

Fig. (2): Nasal dissection on the cartilaginous framework.

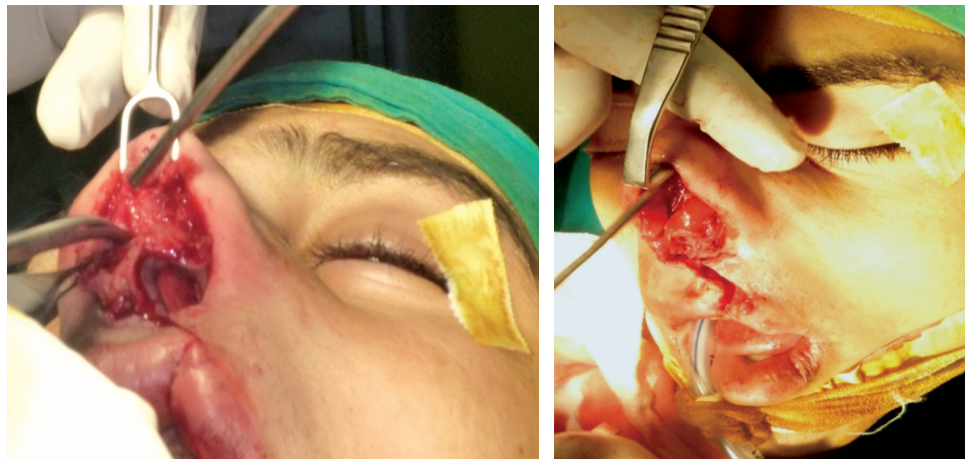

Fig. (3): Different types of tip grafts:



(A): Costal cartilage.

(B): Septal cartilage.

(C): Auricular cartilage.



Table (1): Types of used nasal tip sutures.

Type of tip suture	Number of patients
Trans-domal suture	15
Inter-domal suture	12
Steal (Lateral crus suture)	8
Spring suture	5

Table (2): Types of used nasal tip grafts.

Types of tip graft	Number of patients
Columellar strut	23
Umbrella graft	11
Onlay tip graft	10
Sub-domal graft	9
Anchor graft	6
Cap graft	6

*Secondary procedures for tip rhinoplasty:*

As regards to the secondary procedures for correction of the nasal deformity, various procedures were used as tabled in (Table 3).

Table (3): Secondary procedures used in repair of cleft lip nasal deformity.

Secondary procedures	Number of patients
<i>Air way patency:</i>	
Strengthening of the LLC by tip grafts	25
Spreader grafts	19
<i>Columellar skin lengthening:</i>	
Bardach's V - Y technique	3
Scar flap	1
Bipedicled nasal floor flap	1
<i>Augmentation of the pyriform aperture:</i>	
Premaxillary graft	13
<i>Symmetization:</i>	
Inter-domal suture	12
Freeing and repositioning of LLC by over-lapping on the ULC	6
Caudal septal extension graft	6
<i>Dorsum:</i>	
Dorsal on lay graft (in deficient dorsum)	
Nasal bone reduction (in humpy nose)	6
<i>Alar rim:</i>	
Alar contour graft	17
Alar spreader graft	8
Repositioning of the alar base	8
<i>Alar web:</i>	
Z-plasty	4
<i>Osteotomy:</i>	
Medial and lateral osteotomies	3

*Evaluation of the outcome:*

The patients were underwent follow-up in the outpatient clinic for 12 months and the post-operative outcomes were evaluated as follow:

- Subjective satisfaction: Either excellent, good, fair or poor.
- Objective cosmetic appearance: Via comparing the pre-and post-operative photos.
- Nasal tip shape and site.
- Development of secondary deformity.
- Post-operative complications: Infection, disruption, and necrosis.
- Functional improvement of the pre-operative symptoms, as difficulty of breathing or change in the voice, if present.

*Statistical analysis:*

Descriptive statistics such as frequency and percentages were used to summarize the collected data (qualitative data). Comparison between the different groups of patients was carried out using the test of proportion (Z-test; to compare between two proportions). *p*-values for calculated test statistics were obtained. A *p*-value >0.05 was considered Non Significant (NS), *p*-value <0.05 was considered statistically Significant (S) and a *p*-value <0.001 was considered Highly Significant (HS). All statistical analyses were carried out in STATA/SE version 11.0 for Windows.

**RESULTS**

This study included 25 patients coming for rhinoplasty. They were 14 females and 11 males. The age of the patients ranged from thirteen years to thirty one years (average 17 years). There were 4 patients having no previous attempts for cleft lip repair, while the rest of the patients (21 patients) had repaired cleft lip. Only 5 patients had history of primary rhinoplasty during early repair of the cleft lip with residual secondary nasal deformity, while 20 patients had no previous attempts for repair the cleft lip nasal deformity. Out of the 25 patients, only 3 patients had bilateral cleft lip, while the other 22 patients had unilateral cleft lip.

The operations took a duration range from 2 hours and 15 minutes up to 3 hours and 40 minutes, with the mean duration 2 hours and 55 minutes.

*Evaluation of the outcome:**1- Subjective satisfaction:*

The general degree of subjective satisfaction regardless to the used method of tip rhinoplasty is illustrated in (Fig. 4).



The type of used graft (the site of the taken graft) affected the net patient satisfaction. The study revealed that use of costal cartilage as a graft is the most superior results as it showed no patients with poor satisfaction among the operated patients. While the use of septal cartilage showed a statistically highly significant difference and auricular cartilage was the least satisfying among the patients (Table 4) and (Fig. 5).

The subjective satisfaction seems to be more obvious in male more than females (Table 5) (Fig. 6).

## 2- Objective evaluation of the nasal tip:

After the operation, the nasal tip was evaluated objectively regarding to its shape and site. Generally, most of the patients had accepted net nasal tip shape, site and pointing (20 patients) while the rest of the patients had residual deformity (Table 6) (Fig. 7).

The residual deformities after tip rhinoplasty were ranged from wide (flat) nasal tip, bulky nasal tip to deviated tip. The incidence of each residual deformity is tabled in (Table 7) and illustrated in (Fig. 8).

It was found that the tip definition was greatly affected by the type of nasal tip graft (Table 8) (Fig. 9).

Also, it was found that the tip definition was greatly affected by the type of nasal tip graft according to the site taken from. The costal cartilage recorded a highly statistically significant results, the septal cartilage showed a statistically significant results. While, the auricular cartilage failed to achieve any statistical significance (Table 9) (Fig. 10).

## 3- Development of secondary deformity:

The post-operative secondary deformities are listed in (Fig. 11).

There was a statistically highly significant relation between the development of secondary deformities and each type of the used graft (Table 10) (Fig. 12).

## 4- Post-operative complications:

During the course of the study, we were confronted with a number of complications, such as surgical site infection (SSI), epistaxis, contact dermatitis, and wound disruption (Fig. 13).

## 5- Functional improvement of pre-operative complaints:

There were 5 patients were complaining of difficulty in breathing, either due to defective internal or external nasal valve (differentiated by using tape test). All of them showed obvious improvement in their complaints. While there were 3 patients with abnormally nasal tone of the voice, only one of them noticed improvement in his complaint (Table 11).

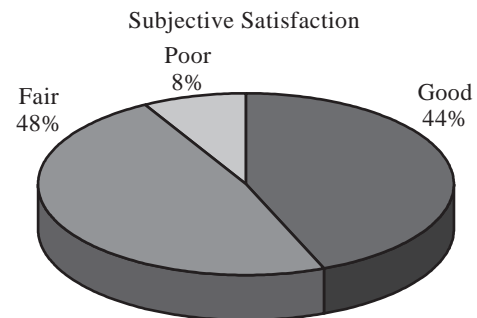


Fig. (4): Subjective satisfaction distribution among the operated patients.

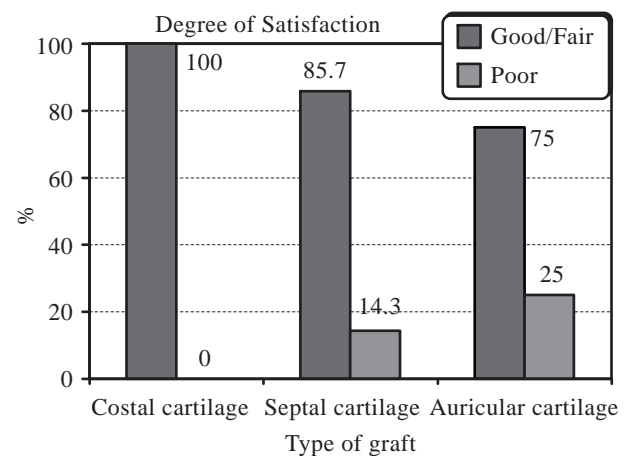


Fig. (5): Subjective satisfaction distribution among the operated patients according to the type of graft (according to the taken site).

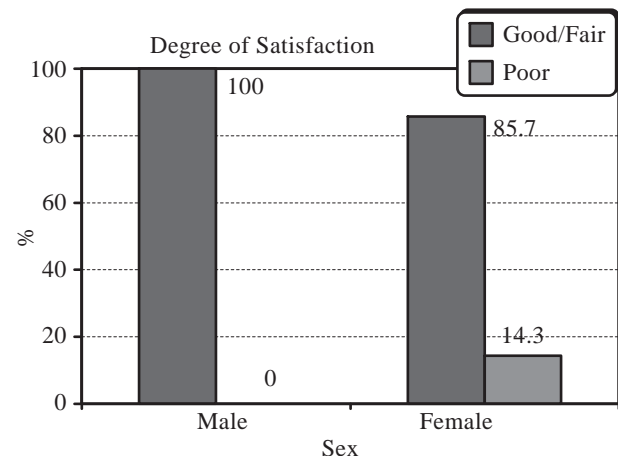

Fig. (6): Subjective satisfaction distribution among patients by the sex of the patient.

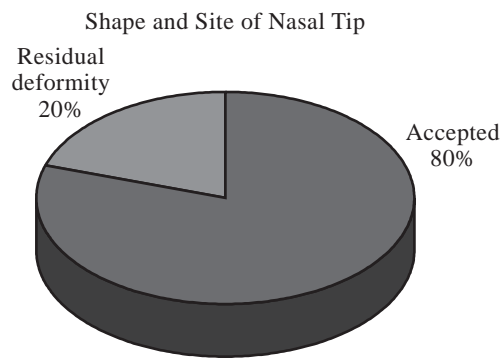


Fig. (7): Distribution of the nasal tip shape and site among the operated patients.

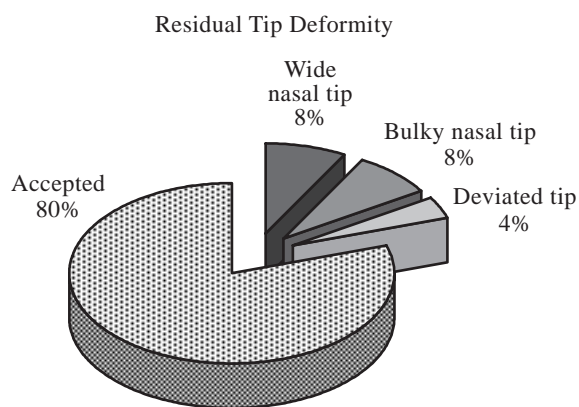


Fig. (8): Residual nasal tip deformity among the operated patients.

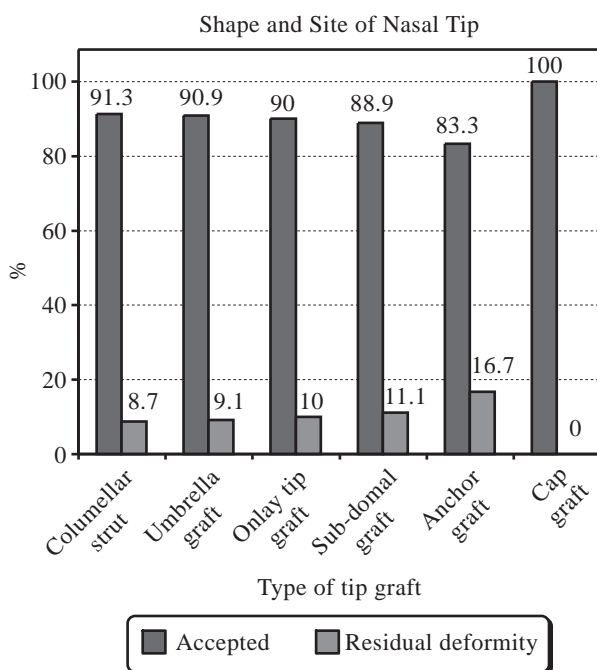


Fig. (9): Distribution of residual nasal tip deformity according to the used tip graft.

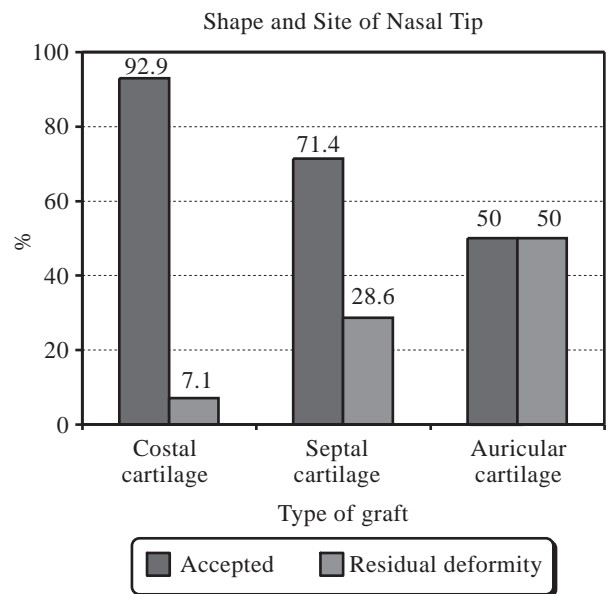


Fig. (10): Distribution of residual nasal tip deformity according to the taken site of used graft.

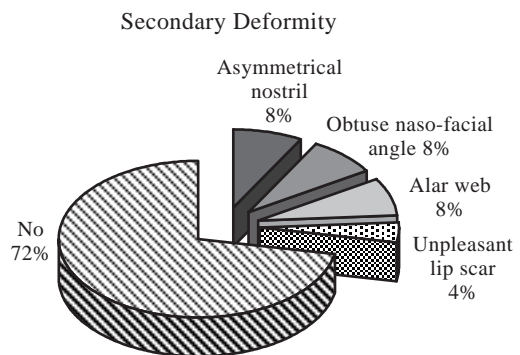


Fig. (11): Post-operative secondary deformities.

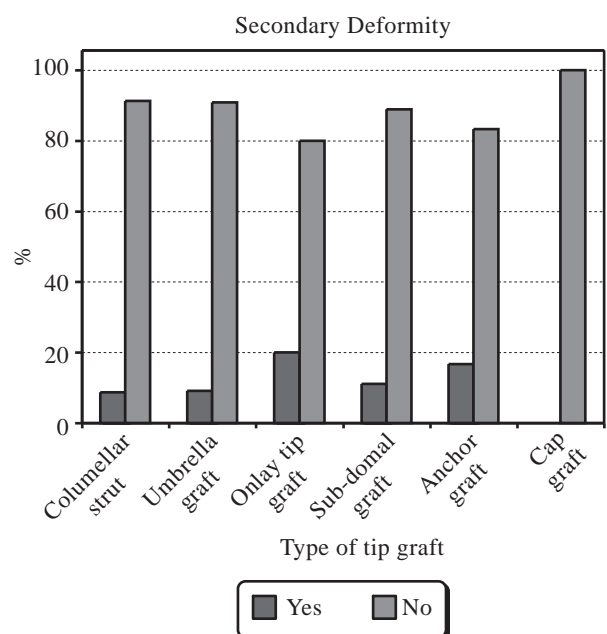


Fig. (12): Distribution of Post-operative secondary deformities according to the used grafts.

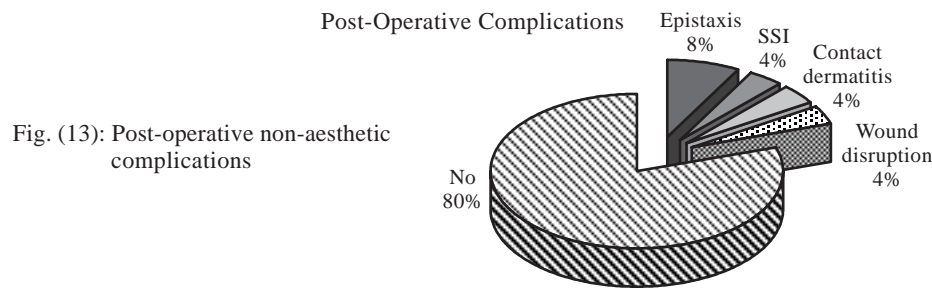


Table (4): Subjective satisfaction distribution among the operated patients according to the type of graft (according to the taken site).

Type of graft	No. of patients	Degree of satisfaction				Z	p-value
		Good/Fair		Poor			
		No.	%	No.	%		
Costal cartilage	14	14	100.0	0	0.0	–	–
Septal cartilage	7	6	85.7	1	14.3	5.40	<0.001
Auricular cartilage	4	3	75.0	1	25.0	2.31	0.02

$p < 0.001$  Highly Significant (HS) difference.  $p = 0.02$  Significant (S) difference.

Table (5): Subjective satisfaction distribution among patients by the sex of the patient.

Sex	No. of patients	Degree of satisfaction					
		Good		Fair		Poor	
		No.	%	No.	%	No.	%
Male	11	6	54.5	5	45.5	0	0
Female	14	5	35.7	7	50	2	14.3

Table (6): Distribution of the nasal tip shape and site among the operated patients.

	Shape and site of nasal tip	
	Accepted	Residual deformity
No. of patients	20	5
Percentage	80%	20%

Table (7): Residual nasal tip deformity among the operated patients.

Residual tip deformity	No. of patients	%
Wide nasal tip	2	8
Bulky nasal tip	2	8
Deviated tip	1	4

Table (8): Distribution of residual nasal tip deformity according to the used tip graft.

Type of tip graft	No. of patients	Shape and site of nasal tip				Z	p-value
		Accepted		Residual deformity			
		No.	%	No.	%		
Tip suturing and diced tip graft	23	21	91.3	2	8.7	14.05	<0.001
Umbrella graft	11	10	90.9	1	9.1	9.43	<0.001
Onlay tip graft	10	9	90.0	1	10.0	8.43	<0.001
Sub-domal graft	9	8	88.9	1	11.1	7.43	<0.001
Anchor graft	6	5	83.3	1	16.7	4.37	<0.001
Cap graft	6	6	100.0	0	0.0		—

$p < 0.001$  Highly Significant (HS) difference.

Table (9): Distribution of residual nasal tip deformity according to the taken site of used graft.

Type of graft	No. of patients	Shape and site of nasal tip				Z	p-value
		Accepted		Residual deformity			
		No.	%	No.	%		
Costal cartilage	14	13	92.9	1	7.1	12.50	<0.001
Septal cartilage	7	5	71.4	2	28.6	2.50	0.01
Auricular cartilage	4	2	50.0	2	50.0	0.00	1.00

$p < 0.001$  HS difference.  $p = 0.01$  Significant (S) difference.  $p = 1.00$  Non Significant (NS) difference.



Table (10): Distribution of Post-operative secondary deformities according to the used grafts.

Type of tip graft	No. of patients	Secondary deformity				Z	p-value
		Yes		No			
		No.	%	No.	%		
Columellar strut	23	2	8.7	21	91.3	14.05	<0.001
Umbrella graft	11	1	9.1	10	90.9	9.43	<0.001
Onlay tip graft	10	2	20.0	8	80.0	4.74	<0.001
Sub-domal graft	9	1	11.1	8	88.9	7.43	<0.001
Anchor graft	6	1	16.7	5	83.3	4.37	<0.001
Cap graft	6	0	0.0	6	100.0	–	–

$p < 0.001$  HS difference.

Table (11): Post-operative improvement of functional symptoms.

Functional symptom	No. of patients	Improvement	
		Yes	No
Difficult breathing	5	5	0
Nasal tone of the voice	3	1	2

## Selected Cases:

## Case (1)

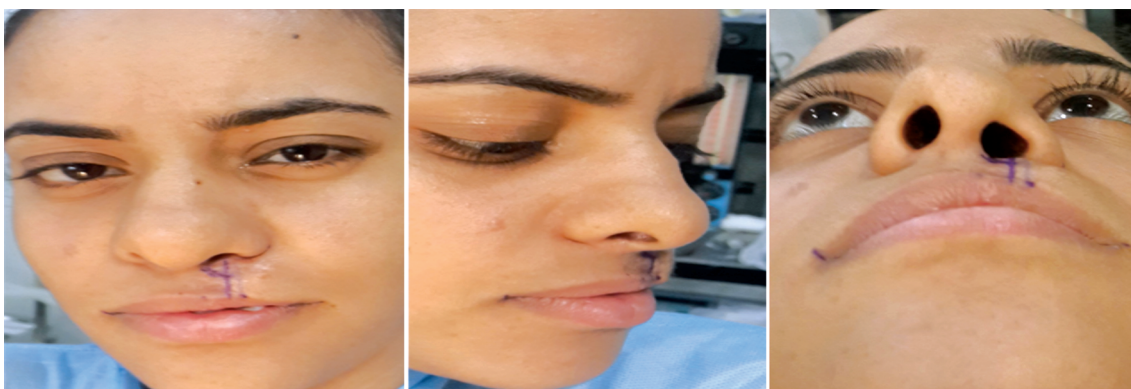

Fig. (14): Frontal, lateral and basal pre-operative views of the second selected case.




Fig. (15): Frontal, lateral and basal views 6 months post-operative of the second selected case.

- Twenty years old female patient.
- *Analysis of the nasal deformities:*
  - Frontal view: Asymmetrical nostril.
  - Lateral view: Ill-defined tip.
  - Basal view: Flaring of the left nostril, central columella, C-shaped septum, under-developed pyriform aperture and cleft nasal sill.
- *She underwent:*
  - Revision of the cleft lip deformity to close the nasal sill cleft.
  - Tip sutures: As interdomal and lateral crural mattress sutures.
  - Nasal grafts:
    - o Diced cartilage for augmentation of the pyriform aperture.
    - o Columellar strut, spreader, alar rim and nasal tip (on lay) grafts using auricular cartilage graft.

Case (2)

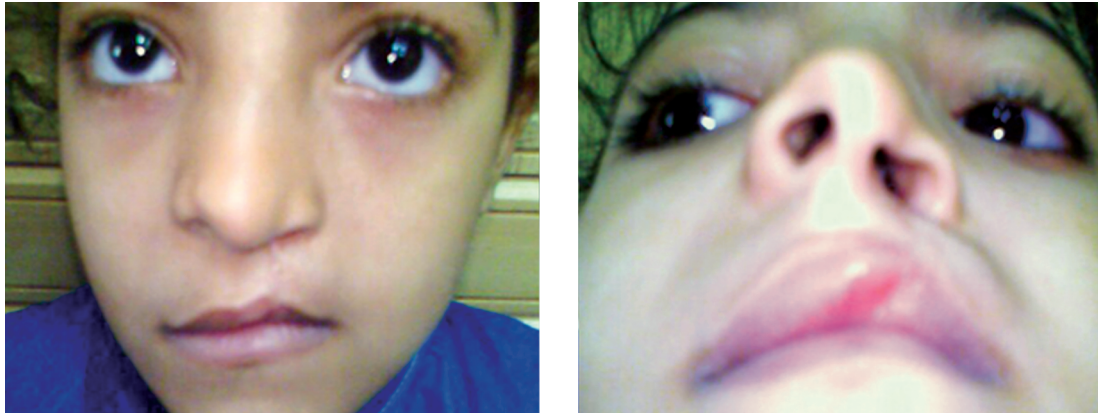


Fig. (16): Frontal and basal pre-operative views of the fifth selected case.

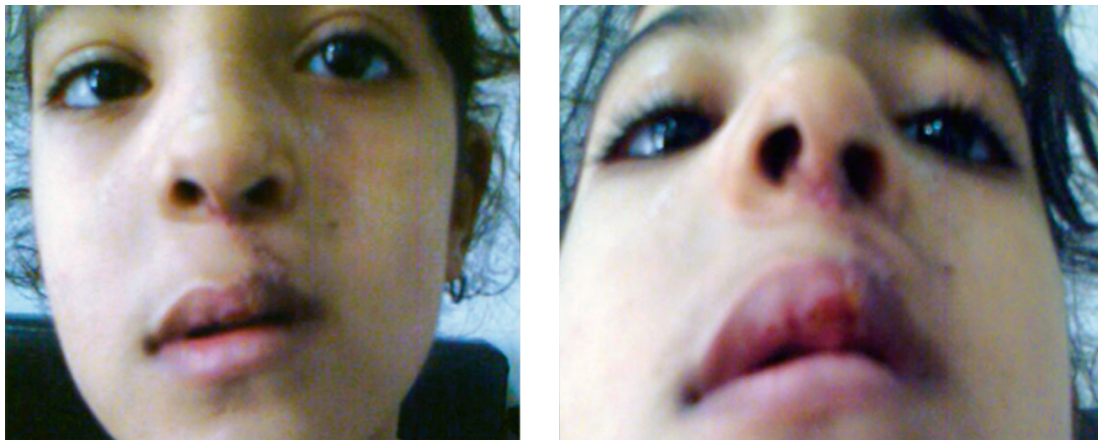


Fig. (17): Frontal and basal views 2 weeks post-operative of the fifth selected case.

- Fourteen years old female patient.
- *Analysis of the nasal deformities:*
  - Frontal view: Deviated nasal tip, asymmetrical nostrils as well as shortened lip scar causing notched white line.
  - Basal view: Flaring and widening of the left nostril with short columella deviated tip, cleft nasal sill and under-developed pyriform aperture.
- *She underwent:*
  - Revision of the cleft lip deformity to close the nasal sill cleft.
  - Tip sutures: As transdomal, columella-septal suture and lateral crural mattress sutures.
  - Nasal grafts:
    - o Diced cartilage for augmentation of the pyriform aperture.
    - o Columellar strut, spreader, alar rim and anchor as well as subdomal tip grafts using costal cartilage graft.

## DISCUSSION

Nasal deformity associated with cleft lip has been viewed as one of the most challenging reconstructive problems in rhinoplasty. The complexity of cleft lip rhinoplasty is demonstrated by the abundance of technique that is available for its correction. Yet, there is no conclusively superior technique among those that were described to date [5].

The universal goal of nasal tip surgery is to create a stable, symmetric, and aesthetically projected and rotated nasal tip that is triangular at base view and harmonious with the rest of the nose, improving its overall visual appeal [6].

This study tried to explore the different surgical options for reconstruction of the nasal tip in cases of secondary cleft lip nasal deformity, evaluate of their esthetic and functional results and demonstrate the subjective satisfaction for each case.

A debate is going on whether to attempt immediate manipulation of alar cartilage to correct the deformity or to postpone the management until full growth of the nose. This was done on the assumption that early dissection of the alar and septal cartilage may interfere with the normal development of the nose [7].

Sykes stated that primary rhinoplasty at the time of cleft lip repair can improve the cleft lip

nasal deformity by achieving better symmetry, which allow the nose to grow in a symmetric fashion, and potentially improve long-term outcomes [8].

However, this study included 25 patients coming for rhinoplasty, all of them had delayed cleft lip nasal deformity, and any patient with early primary nasal deformity were excluded from the selected patients in the current study. Accordingly, this study cannot answer the question whether early repair of the nasal deformity could be attempted without jeopardizing the normal nasal growth.

The outcomes of the operations were evaluated subjectively as well as objectively regarding to aesthetic and functional perspectives.

In order to overcome the relatively limited number of patients, from the statistical point of view, we were forced to merge good and fair degrees of satisfaction into one item (accepted outcome) to be compared with poor degree of satisfaction in certain items.

In all cases involved in the current work, external approach was done. This had the advantage of exposing both sides of the nose so that the anatomy on the healthy side was used as reference for correction of the deformed side. In addition this adequate exposure had allowed accurate placement of the cartilage grafts and sutures used to correct deformities. This approach is the most universally accepted one [9].

Regarding to the general degree of subjective satisfaction, 92% of the operated patients were accepting the aesthetic outcome (44% of the recorded good results, and 48% recorded fair results). On the other hand, only 8% of the operated patients recorded poor degree of satisfaction. These results are comparable and in agreement with [10].

Regarding to the type of the used grafts, we depended only on the autologous cartilaginous grafts. Although different types of other autologous grafts, as boney grafts, as well as allograft substitutes were mentioned in the literatures, autologous cartilaginous grafts were preferred to avoid the undesirable disadvantages of the other substitutes as resorption and difficult handling, regarding to the bone graft, and the recorded universal long term complications with unsatisfactory results in cases of allografts [11,12]. However, this concept does not agree with Lohuis, who preferred synthetic materials over autologous grafts because of their immediate availability, lack of donor-site morbidity,

better adaptability, good immediate results, and low costs [13].

Although generally the use of tip grafts significantly affect the results regardless to the donor site, the costal cartilage record the most satisfying outcome regarding to patient's satisfaction as well as objective evaluation of the nasal tip appearance, followed by the septal cartilage and then and lastly, the auricular cartilage. This conclusion was also stated by Araco et al. and Gunter [14,15].

It was found that each type of tip graft significantly affect the ultimate nasal tip appearance. Also it was concluded that using umbrella, onlay tip graft, columellar strut, subdomal and cap grafts recorded the most significant affection of the degree of patient's satisfaction. Relatively same results were approached by Park et al. and Cochran & Landecker, stated that complications and suboptimal results do occur, even for experienced surgeons. A thorough knowledge of the principles of postoperative management of these complications can minimize their deleterious effects and preserve an aesthetic outcome [16,17].

Cleft lip nasal deformity are not only associated with cosmetic complaints, but also accompanied by functional symptoms. In this study, two main functional complaints were found; nasal breathing difficulty due to deformed valves and nasal tone of speech. Augmentation rhinoplasty with correction of both internal and external nasal valves showed complete improvement in their breathing complaints, but unfortunately failed to achieve the same marvelous results regarding the abnormal voice tone. The same improvement in the nasal breathing was recorded by Caithanyaa [18]. However, on the other hand Huempfer-Heirl concluded that augmentation cleft rhinoplasty makes no improvement regarding the functional complaints [19].

### *Conclusion:*

A naturally looking nasal tip projection not only determines the patients' degree of satisfaction but also is considered the ultimate aesthetic as well as functional goal the surgeons. Nasal grafts are essential for considerable good outcomes for cases of cleft nasal deformity. Autologous cartilaginous grafts are the most suitable type of nasal grafts, and costal cartilage graft is the most superior between them.

Further studies are needed to justice if primary rhinoplasty is beneficial or it disturbs the nasal



symmetry and leave scared tissues for a potential future intervention.

## REFERENCES

- 1- Blair V. and Brown J.B.: Nasal abnormalities, fancied and real surgery. *Gynecol. Obstet.*, 53:797-819, 1931.
- 2- Jackson I.: Repair of secondary cleft lip and nose deformities. In McCarthy J.G. et al., *Current therapy in plastic surgery*, 1<sup>st</sup> edition, Vol. 2, Philadelphia, Saunders, Elsevier, P. 458, 2009.
- 3- EL-Bestar and Mansour O.: Cleft lip nasal deformities: Primary repair, *Egyptian J. Plast. Reconstr. Surg.*, 458-466, 2006.
- 4- Lo L. and Chen Y.: Simultaneous reconstruction of the secondary bilateral cleft lip and nasal deformity: Abbe flap revisited, *Ann. Plast. Reconstr. Surg.*, 1219, 2002.
- 5- Szycha P., Rykala J. and Kruk-Jeromin J.: Individual and ethnic aspects of preoperative planning for posttraumatic rhinoplasty; *European Journal of Plastic Surgery*, Vol. 34, No. 4, pp. 245-249, 2011.
- 6- Benlier E., Top H. and Aygit A.: Management of the long nose: Review of techniques for nasal tip supporting structures. *Aesthrtic Plast. Surg.*, 33: 159-168, 2009.
- 7- Lo L.: Primary correction of the unilateral cleft lip nasal deformity: Achieving the excellence. *Chang Gung Medical Journal*, 29: 262-267, 2006.
- 8- Sykes J.: The importance of primary rhinoplasty at the time of initial unilateral cleft lip repair. *Arch. Facial Plast. Surg.*, 12: 53-55, 2010.
- 9- Raspall G., Gonzfilez L. and Lagunas J.: Management of the nasal tip by open rhinoplasty. *Journal of Cranio-Maxillofacial Surgery*, 28: 145-150, 2010.
- 10- Ashoor T.: Evaluation of the outcome after repair of cleft lip nasal deformity. M.Sc. Thesis, Cairo University, P94, 2008.
- 11- Tosun Z., Karabekmez F., Keskin M., Duymaz A. and Savaci N.: Allogeneous cartilage graft versus autogenous cartilage graft in augmentation rhinoplasty: a decade of clinical experience, *Aesthetic Plastic Surgery*, Vol. 32, No. 2, pp. 252-260, 2008.
- 12- Bateman N. and Jones N.: Retrospective review of augmentation rhinoplasties using autologous cartilage grafts. *J. Laryngol. Otol.*, 114: 514-518, 2000.
- 13- Lohuis P., Watts S. and Vuyk H.: Augmentation of the nasal dorsum using Gore-Tex: Intermediate results of a retrospective analysis of experience in 66 patients. *Clin. Otolaryngol. Allied Sci.*, 26: 214-217, 2001.
- 14- Araco A., Gravante G., Araco F., Castri F., Delogu D., Filingeri V., Casciani C. and Cervelli V.: Autologous cartilage graft rhinoplasties. *Aesthetic Plast. Surg.*, 30: 169-174, 2006.
- 15- Gunter J.: Tip rhinoplasty a personal approach. *Plast. Reconstr. Surg.*, 110 (4): 204-226, 1999.
- 16- Park B., Lew D. and Lee Y.: A comparative study of the lateral crus of alar cartilages in unilateral cleft lip nasal deformity. *Plast. Reconstr. Surg.*, 101: 915-920, 1998.
- 17- Cochran C. and Landecker A.: Prevention and management of rhinoplasty complications. *Plast. Reconstr. Surg.*, 122: 60-71, 2011.
- 18- Caithanyaa N., Rai K., Shivnkumar H. and Upasi A.: Evaluation of the outcome of secondary rhinoplasty in cleft lip and palate patients. *Journal of Plastic, Reconstructive & Aesthetic Surgery*, 46 (1): 27-33, 2011.
- 19- Huempferner-Hierl H., Hemprich A. and Hierl T.: Results of a prospective anthropometric and functional study about aesthetics and nasal respiration after secondary rhinoplasty in cleft lip and palate patients. *J. Craniofac. Surg.*, 20 (2): 1863-1875, 2009.